

OSTEONECROSIS OF THE JAW AND BISPHOSPHONATE: PREVENTION, DIAGNOSIS AND TREATMENT.


OSTEONECROSI DEI MASCELLARI DA BISFOSFONATI: PREVENZIONE, DIAGNOSI E TRATTAMENTO.

Palaia G ¹, Tenore G ¹, Carpenteri F ¹, Capocci M¹, Romeo U¹

¹ Department of Odontostomatologic and Maxillofacial Science, Faculty of Medicine and Odontology, "Sapienza" University of Rome, Italy. Director: Prof. Antonella Polimeni

¹ UOC Odontostomatologic Clinic. Director 2nd level: Prof. Massimo De Luca

¹ Master EMDOLA (European Master Degree in Oral Laser Applications): Director: Prof. Umberto Romeo

 ¹ Dipartimento di Scienze Odontostomatologiche e Maxillo Facciali, Facoltà di Medicina e Odontoiatria, Sapienza Università di Roma. Direttore: Prof. Antonella Polimeni

¹ UOC di Clinica Odontostomatologica. Dirigente II Livello: Prof. Massimo De Luca

¹ Master EMDOLA (European Master Degree in Oral Laser Applications): Direttore: Prof. Umberto Romeo

Citation: Palaia G, Tenore G, Carpenteri F, et al. Osteonecrosis of the jaw and bisphosphonate: prevention, diagnosis and treatment. Prevent Res 2012; 2 (1): 27-35

Key words: osteonecrosis, jaw, bisphosphonates

 **Parole chiave:** osteonecrosi, ossa mascellari, bisfosfonati

Abstract

Background: Osteonecrosis of the jaws in patients treated with bisphosphonates (ONJ-BF) is a multidisciplinary medical problem that has aroused considerable interest. In recent years several reports of osteonecrosis of the jaws in patients treated with BF have appeared.

Objectives: Despite numerous scientific and epidemiological studies, a lot of doubts still persist and it is currently not possible to make significant progress in clarifying the clinical approach to patients using ONJ-BF. Our paper wants to offer a review about the mechanism and the elements of the various diagnostic and therapeutic modalities that can be used against this clinical phenomenon.

Methods: Dental procedures seem to increase the frequency of ONJ-BF, but it is possible that a preexisting subclinical ONJ-BF appears as a dental disease or, alternatively, that the extraction or dental procedures reveal a half hidden osteonecrosis.

Results: In normal conditions, this could rapidly heal without infectious consequences, even if the mouth is not a sterile environment. In patients developing ONJ-BF the recovery is rather slow and difficult, due to contamination of the bone lesion with germs by the bacterial flora of the oral cavity.

Conclusions: The complex clinical and medico-legal implications require that all health workers, dentists, dental hygienists, oral and maxillo-facial surgeons, have an adequate knowledge of the diagnostic processes and the general principles for the prevention of this disease.

Abstract

Introduzione: L'osteonecrosi dei mascellari nei pazienti in terapia con bisfosfonati (ONJ-BF) rappresenta un problema medico multidisciplinare che ha suscitato notevole interesse sia in ambito nazionale che internazionale. Negli ultimi anni sono comparse nel mondo sempre più numerose segnalazioni di osteonecrosi dei mascellari insorte in pazienti trattati con BF.

Obiettivi: Nonostante i numerosi studi scientifici ed epidemiologici, i punti oscuri sono moltissimi ed ancora non si è riusciti a fare completa chiarezza nell'approccio clinico da adottare in presenza di pazienti in terapia con questi farmaci. Nel presente lavoro verrà eseguita una disamina dell'eziopatogenesi, degli elementi diagnostici e delle diverse modalità terapeutiche da poter adottare nei confronti di tale fenomeno clinico.

Metodi: L'intervento odontoiatrico sembra aumentare la frequenza di una ONJ-BF, tuttavia è possibile che una preesistente ONJ-BF in forma subclinica si manifesti come patologia dentaria o, in alternativa, che l'estrazione o l'intervento odontoiatrico sveli una sottostante osteonecrosi.

Risultati: In condizioni normali si assisterebbe ad una guarigione rapida senza sequele infettive, anche se il cavo orale non è un ambiente sterile. Nei soggetti che sviluppano ONJ-BF la guarigione è invece lenta e difficoltosa, con tendenza alla contaminazione della lesione ossea con germi della flora batterica del cavo orale.

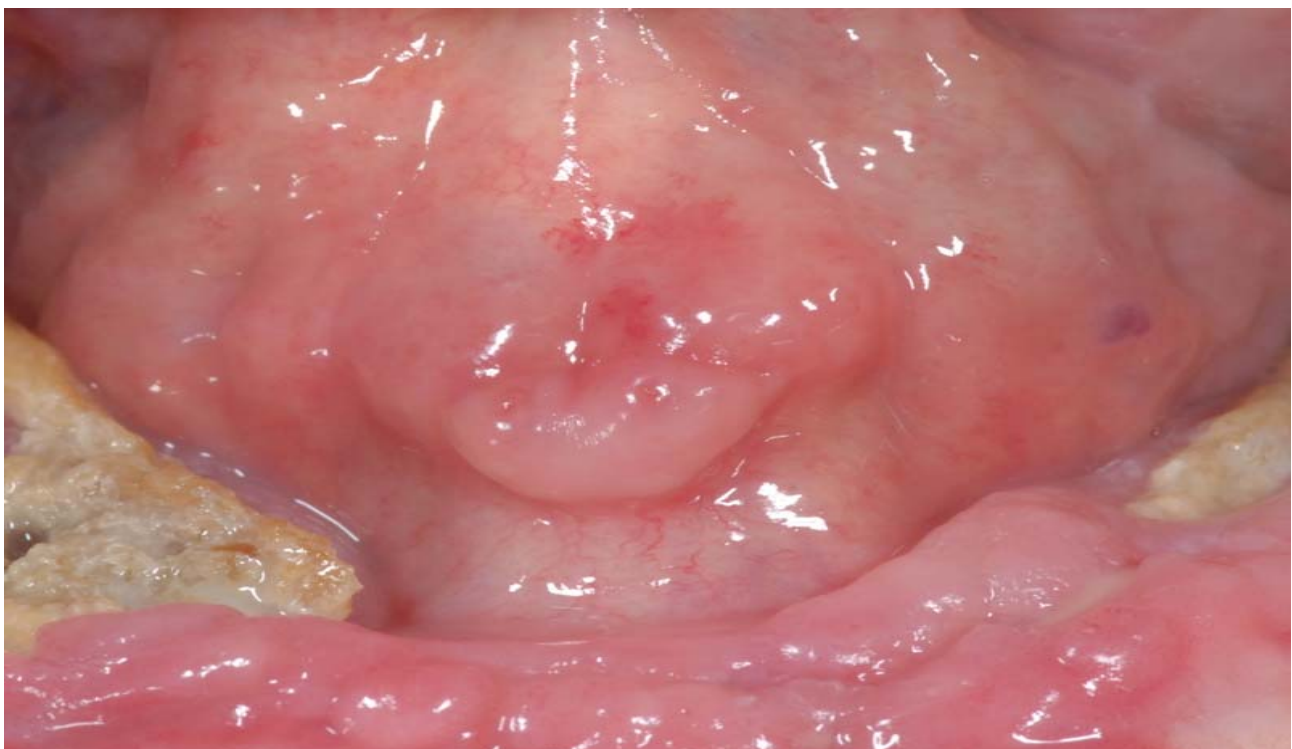Conclusioni: Le complesse implicazioni cliniche e medico-legali impongono a tutti gli operatori sanitari, odontoiatri, igienisti dentali, chirurghi orali e maxillo-facciali, una adeguata conoscenza dei processi diagnostici e dei principi generali di prevenzione di tale patologia.

Introduction

Osteonecrosis of the jaws, on the basis of ischemic, is not an autonomous disease but rather the consequence of many local or systemic factors able to modify the blood flow inside the bone and tissue coating and expose the anatomical region to the action of several additional factors. Among the various risk factors, we find: *local risk factors* (radiotherapy of head and neck, dental surgical procedures involving bone, etc.); *systemic risk factors* (corticosteroid therapy, hemodialysis, etc.); *iatrogenic risk factors* (arsenical derived products, incongruous use of root-canal irrigating solutions).

Osteonecrosis of the jaw from bisphosphonates (ONJ-BF) is a side effect of prolonged treatment with the BFs first officially described by Marx in 2003 (1). It is characterized by spontaneous or induced exposure of necrotic bone at the jaw and / or the upper jaw that persists for longer than 8 weeks in a patient who has taken or is taking a drug class of bisphosphonates and who is/was not subjected or exposed to radiation of said bone segments (Figure 1).

Figure 1: Clinical aspect of ONJ-BF

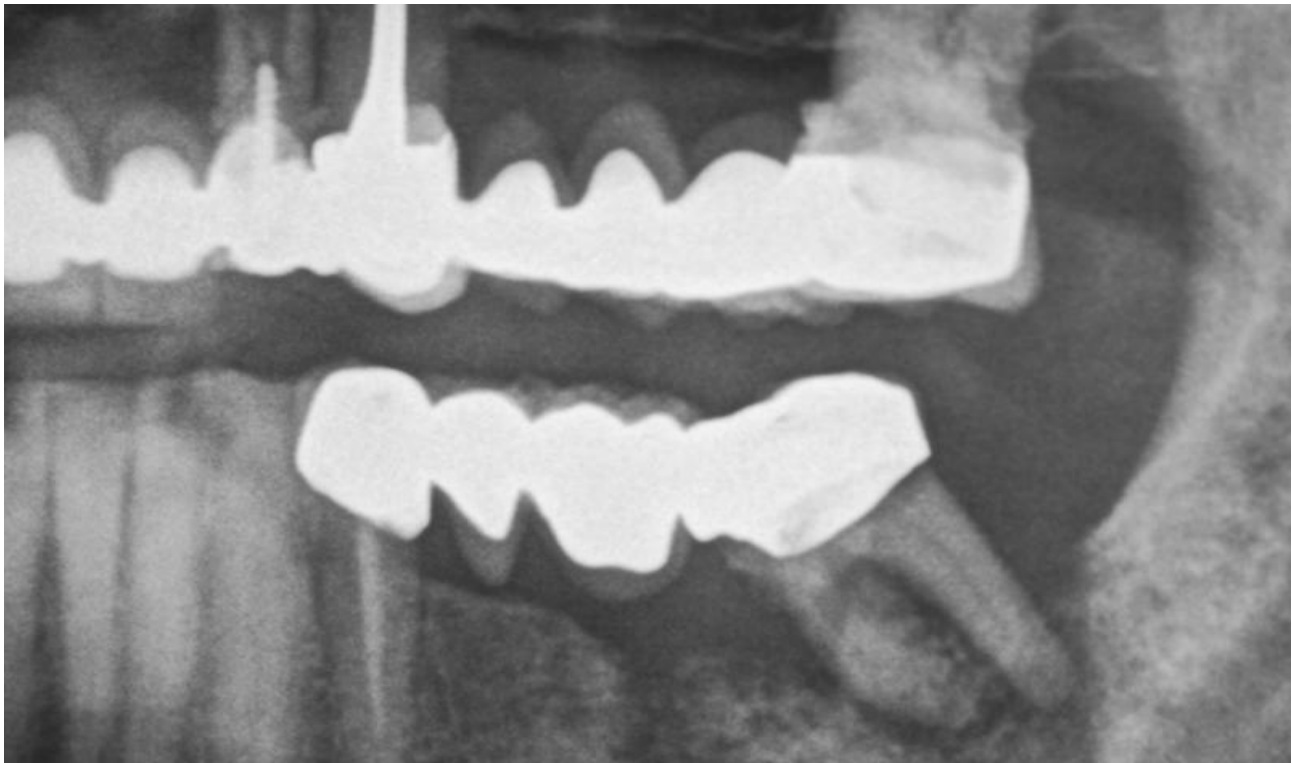


The fundamental biological action of all bisphosphonates, assumed both orally and intravenously, is represented by inhibition of resorption (anti-osteoclastic action) and then the turnover and renewal of the bone tissue (with the consequent reduction of the calcium levels in serum). By virtue of this mechanism of action, these drugs are used for the treatment of various benign or malignant bone diseases, mainly represented by osteoporosis, Paget's disease, multiple myeloma and osteolytic bone metastases of carcinomas, resulting among the most prescribed drugs in the world.

The BF-ONJ can occur after invasive surgical dental treatments (tooth extraction, endodontic surgery). In patients with impaired immune system, we can have bone necrosis occurrence resulting from dento-periodontal diseases. A BF-ONJ not always develops after dental procedures (*iatrogenic forms*); some ONJ-BF cases described in literature occur without an appropriate temporal relationship with iatrogenic traumatic events (*natural forms*).

The ONJ can sometimes be observed through an orthopantomographic radiography of the jaws but in case of suspicion or uncertainty, second-level examinations such as computed tomography and nuclear magnetic resonance imaging can provide more information even in the early stages of the disease about extension of the necrotic process (Figure 2).

Figure 2: Particular of X-ray showing osteonecrosis area



The dental work appears to increase the frequency of a ONJ-BF, however, it is possible that a pre-existing ONJ-BF in subclinical form is manifested as dental disease or, alternatively, that the extraction or the dental work reveals an underlying osteonecrosis. Bone lesions are observed mainly on the mandible (65%), especially in the mylohyoid ridge; the maxilla is involved in 26% of cases, especially at the level of alveolar bone and palatal torus. In 9% of cases, the lesions are multiple and affect both the mandible and maxilla (2). Under normal conditions this could mean a quick recovery without infections, even if the mouth is not a sterile environment.

In subjects who develop ONJ-BF, healing is rather slow and difficult, with a tendency to contamination of the bone lesion with germs of the bacterial flora of the oral cavity. A distinction must be made between BF-induced ONJ, administered intravenously, and those induced by drugs administered orally, in that the latter appears to be less frequent and more responsive to the suspension of the drug and the surgical removal.

Objectives

Since 2003 various classifications have been proposed. In 2006 *Ruggiero et al.* (3) drew up a classification of 5 different stages in relation to clinical characteristics and therapeutic opportunities, revised in 2009 in the position paper about ONJ BF by American Association of Oral and Maxillofacial Surgeons (AAOMS) (4) (Table 1).

Table 1: *Staging and treatment strategies**

Stage	Description	Treatment Strategies
Pre – ONJBF (At risk category)	No apparent necrotic bone in patients who have been treated with either oral or IV bisphosphonates	No treatment indicated, patient education.
Stage 0	No clinical evidence of necrotic bone, but nonspecific clinical findings and symptoms.	Systemic management, including use of pain medication and antibiotics.
Stage 1	Exposed and necrotic bone in asymptomatic patients without evidence of infection.	Antibacterial mouth rinse; Clinical follow-up on quarterly basis; Patient education and review of indications for continued bisphosphonate therapy.
Stage 2	Exposed and necrotic bone associated with infection as evidenced by pain and erythema in region of exposed bone with or without purulent drainage.	Symptomatic treatment with oral antibiotics; Oral antibacterial mouth rinse; Pain control; Superficial debridement to relieve soft tissue irritation.
Stage 3	Exposed and necrotic bone in patients with pain, infection and one or more of the following: exposed and necrotic bone extending beyond the region of alveolar bone, (ie, inferior border and ramus in the mandible, maxillary sinus and zygoma in the maxilla) resulting in pathologic fracture, extraoral fistula, oral antral/oral nasal communication, or osteolysis extending to the inferior border of the mandible or the sinus floor.	Antibacterial mouth rinse; Antibiotic therapy and pain control; Surgical debridement / resection for longer term palliation of infection and pain.

* (American Association of Oral and Maxillofacial Surgeons position paper on bisphosphonate-related osteonecrosis of the jaw - 2009 update. *J Oral Maxillofac Surg.* 2009 May; 67(5 Suppl):2-12.)

Conditions of risk for ONJ-BF are obviously all forms of periodontal disease and dental, both acute and chronic, conditions that predispose, on the one hand, to the alveolar penetration of germs in the cavity and to the formation of abscesses and, on the other, to the need for dental cleaning. The presence of a periodontal disease has been described in 84% of ONJ-BF cases . In addition, patients with compromised immune system and susceptibility to infection, as those with cancer, diabetes, or immunosuppressive therapy with steroids or receiving chemotherapy, are particularly susceptible to periodontal or dental disease and not surprisingly are most at risk of developing ONJ-BF. In subjects with some form of immune deficiency, periodontal disease is often particularly frequent, but gives no conspicuous signs of gingival inflammation evolving silently from the clinical point of view (5). Moreover, periodontitis develops in depth towards the root of the tooth and in some cases, the framework evolves into necrotizing acute periodontitis which can then lead to osteonecrosis, justifying a part of the forms defined as "spontaneous" (6).

In the majority of cases reported in the literature (60 - 85%), the development of ONJ-BF occurred as a result of dental work, extractive or implant (iatrogenic forms) (7).

A growing awareness of the problem by dentists has been reached although a clear overview as to the clinical approach to patients treated with these drugs and as to the real rate of risk for different categories of patients exposed to the drug, is still missing . The dental management of patients treated with BPs and the specific management of ONJ-BF are still debated topics worthy of study . Also, their clinical implications involving complex medical-legal issues extend to even wider local and national health policies .

Methods

Prevention strategies

Patients who must take BFev: According to the AAOMS, before starting treatment with bisphosphonates, patients should undergo a thorough odontostomatologic examination, in which all teeth that cannot be cured should be removed, all invasive dental procedures should be completed and optimal periodontal health should be achieved. The goal of treatment for this group of patients is to minimize the risk of developing ONJ.

Asymptomatic patients already treated with BFev: maintaining proper oral hygiene and making regular visits are two key aspects to prevent tooth decay that may require dentoalveolar surgery. Procedures involving direct osseous injury should be avoided as it should be avoided the placement of dental implants.

Asymptomatic patients already treated with BFos: dentoalveolar surgery does not appear to be contraindicated in this group (patients should be adequately informed about the risk, however low, to have impaired bone healing).

Treatment of patients with ONJ-BF

The goal of treatment is to eliminate pain, control infection of hard and soft tissue, hence minimizing the risk of progression of bone necrosis and prevent the emergence of new areas of necrosis. Surgical debridement is variably effective in eliminating the necrotic bone and may also be difficult to get a bone resection with viable bleeding margin as the whole maxilla is exposed to the pharmacological action of bisphosphonates (8).

Drug withdrawal: there is a lack of evidence, in cases reported in the literature, of improvement or failure to progress of ONJ after cessation of BF administration also for relevant periods (up to a year suspension). The BFev persist in the bone up to 12 years after cessation of therapy and BFos persist up to 5 years and it is clear that the interruption of therapy may not help healing ONJ or facilitate the effects of treatments undertaken (9).

Medical therapy: it represents a universally accepted step in the treatment of ONJ. It involves the use of chlorhexidine (0,12 - 0,20%) or hydrogen peroxide (H₂O₂) as antiseptics to make oral rinses 3-4 times a day. As for antibiotic therapy (continuous or intermittent) the use of penicillins (10) is recommended.

Hyperbaric oxygen (HBO): ONJ-BF, unlike osteoradionecrosis, does not seem to respond positively to hyperbaric oxygen therapy. Radiation, in fact, induces a tissue damage characterized by hypoxia, hypocellularity and hypovascularization that can be reversible or improved by the resumption vascular bone and soft tissue (11). In ONJ, bone necrosis has a multifactorial etiology in which the anti-neoangiogenic activity of BF is only partially involved (13). Freiberg, in a recent article, states that hyperbaric oxygen therapy is an adjunct to surgical and antibiotic therapy, and may be useful in treatment of ONJ-BF by producing reactive oxygen and nitrogen species that would positively modulate intracellular signaling molecules involved in bone turnover (13).

Ozone therapy: Ozone causes beneficial effects on blood circulation (especially in small vessels particularly in the tissues in the oral and maxillary bones), increases the concentration of red blood cells and hemoglobin level, promotes diapedesis and phagocytosis and, finally, has also germicides and analgesic effects (9). Iannetti et al. (14), have developed a new protocol for the management of ONJ-BF which includes the use of ozone therapy as a supportive treatment to surgery.

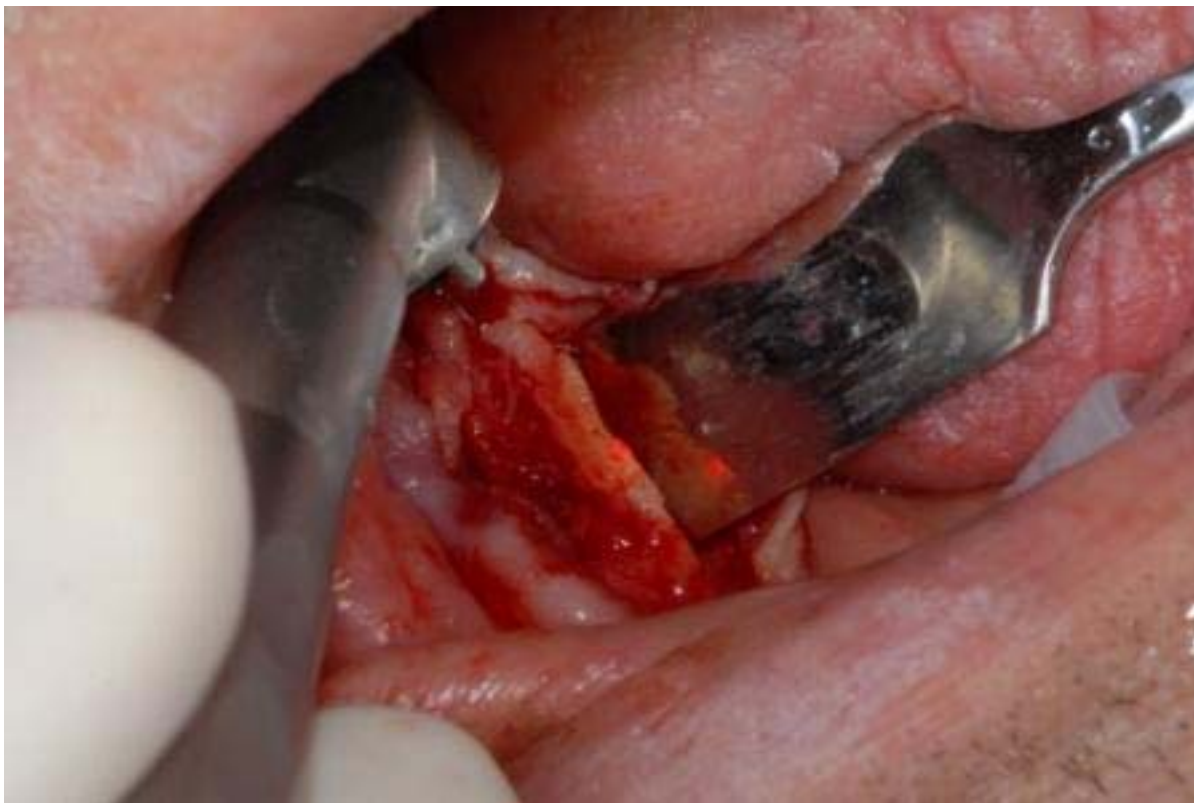Low Level Laser Therapy (LLLT): the studies available to date concerning the operation of low-energy laser in the healing process of soft tissues and bone regeneration, highlight mechanisms at various levels leading to different effects. The LLLT appears to stimulate the proliferation of cells and the formation of new lymphatic and blood vessels. Also, it has proved effective in relieving pain as well as in wound healing and nerve regeneration and has potential anti-microbial and bio-stimulants effects when applied at the level of oral tissues (as also observed by Romeo et al.) (15, 16).

Surgical therapy: the AAOMS emphasizes the need for surgery only for advanced cases of osteonecrosis (stage III) and in the presence of well-defined bone sequestra. The traditional method of conservative surgery provides for any intervention to be performed under antibiotic coverage, limiting itself to eliminate sequestra and mobile bone segments without involving any exposed bone.

Among the many approaches, the conservative surgical treatment of ONJ-BF using *Er: YAG laser* is capable of providing clinical and therapeutic advantages. The beam *Er: YAG laser* works on both the soft tissues without charring but with little haemostatic effect ("cold" laser) and hard tissues, with sharper and non-traumatic cutting action compared with traditional surgery (17, 18).

The absence of haemostatic effect in the *Er: YAG laser* represents an advantage in this case, as it is essential to distinguish, in the surgical phase, the proportion of the avascular necrotic bone from the clinically healthy and vascularized one (bleeding) (Figure 3).

Figure 3: Surgical-conservative approach using *Er:YAG*



Results

The bisphosphonates, administered in patients with benign bone diseases like osteoporosis and malignant such as osteolytic metastases, represent important drugs with beneficial effects (eg. reduction in bone pain, prevention of skeletal complications such as pathologic fractures) hence they are hardly interchangeable. Especially if administered intravenously, compared to bisphosphonates administered orally, they may give rise to ONJ-BF complications.

Medical therapy, local and / or systemic, produces a temporary reduction of pain and local symptoms and is therefore ineffective in the long term (as observed by Vescovi et al. (8), occurring on average recurrence of signs and symptoms of infection three weeks after discontinuation of medical therapy). The conservative surgical approach, even in the early stages of ONJ, finds its rationale in failure of long-term results with medical therapy (it is possible to observe patients not undergoing any invasive therapy, but only in medical therapy, to switch from the early stages of ONJ-BF to advanced stages, resulting in fracture of the jaw) and in other important elements, such as: short traumatic intervention

for the patient for the limited bone involvement, possibility of execution under local anesthesia and healing by primary intention.

Among the various possible approaches, the conservative surgical treatment of ONJ-BF using the Er: YAG laser is able to offer clinical and therapeutic advantages.

They are represented primarily by less traumatic interventions (which, given the frequent systemic impairment of patients with ONJ-BF, turns out to be a fundamental advantage) than traditional surgical approach for absence of vibrations and pressure resulting from the non-use of bone cutters (Er: YAG laser handpiece, which works without coming into contact with the bone tissue, is used during surgery); by the absence of haemostatic effect and peripheral carbonization, which represent two fundamental advantages for distinguishing, during the surgical procedure, the proportion of necrotic and avascular bone from clinically healthy and vascularized (bleeding); by the absence of residual tissue which favours, in combination with the above-mentioned advantages, an optimal healing; by an antibacterial and biostimulant action of the laser beam, which leads to a faster mucosal and bone healing.

Conclusions

Osteonecrosis of the jaws is a severe complication that can result from drug therapy with bisphosphonates, drugs that are prescribed to treat metabolic and oncologic diseases affecting the skeletal system. Risk factors that may contribute to the onset of the disease are varied and related to both systemic and local conditions. In 70-80% of cases, osteonecrosis is manifested by a non-healing or with a delay in the process of healing after a dental extraction or any oral surgery.

In a lower number of cases the disease can spontaneously manifest itself. The early phases are mostly asymptomatic and clinical and radiographic changes have not occurred. With the progress of the disease, the most common symptom reported by patients is an unpleasant sensation of numbness and burning in the mouth. A thorough exploration of the oral mucosa and skin region of the lower third of the face supported by radiographic examination in patients with a history of bisphosphonates helps us to recognize small signs that may raise the suspicion that there is a osteonecrosis process in place.

This phase precedes the appearance of evident osteonecrosis, hence representing an important opportunity for early diagnosis and prevention of the disease. The dental management of patients waiting to start a therapy with bisphosphonates administered intravenously provides an accurate odontostomatological assessment and implementation of an adequate plan for conservative, periodontal and prosthetic treatment designed to eliminate possible local risk factors predisposing to the onset of osteonecrosis.

If surgery is needed and systemic conditions of the patient permit it, bisphosphonate therapy should be postponed until the completion of the mucosal and bone healing process. The management of patients who come to our attention during therapy with bisphosphonates is inspired by the conservative approach and is intended to avoid categorically any bloody action that could act as a stimulus for bone remodeling. The treatment of choice in the case of patients with signs and symptoms of osteonecrosis aims to safeguard the quality of life of these subjects through the control of pain and infectious and dysfunctional complications.

In conclusion, despite the number of questions on pathogenesis, epidemiology and individual susceptibility still remain unresolved today and a close collaboration between dentist, general practitioner, oncologist and orthopedic are deemed to help create the conditions for a valid stage-specific prevention and treatment of osteonecrosis of the jaw associated with use of bisphosphonates.

References

1. Marx RE. Pamidronate (Aredia) and zoledronate (Zometa) induced avascular necrosis of the jaws: a growing epidemic. *J Oral Maxillofac Surg.* 2003; 61 (9): 1115-1157.
2. Ruggiero SL, Fantasia J, Carlson E. Bisphosphonate-related osteonecrosis of the jaw: background and guidelines for diagnosis, staging and management. *Oral Surg Oral Med Oral Pathol Oral Radiol Endod.* 2006; 102 (4): 433-441.
3. Vescovi P, Nammour S. Bisphosphonate-Related Osteonecrosis of the Jaw (BRONJ) therapy. A critical review. *Minerva Stomatol.* 2010; 59 (4): 181-203, 204-213.

4. Ruggiero SL, Dodson TB, Assael LA et al. American Association of Oral and Maxillofacial Surgeons. American Association of Oral and Maxillofacial Surgeons position paper on bisphosphonate-related osteonecrosis of the jaw - 2009 update. *J Oral Maxillofac Surg.* 2009; 67 (Suppl.5): 2-12.
5. Evans CE, Braidman IP. Effects of two novel bisphosphonates on bone cells in vitro. *Bone Miner* 1994; 26 (2): 95-107.
6. Nancollas GH, Tang R, Phipps RJ et al. Novel insights into actions of bisphosphonates on bone: differences in interactions with hydroxyapatite. *Bone* 2006; 38 (5): 617-627.
7. Position paper: epidemiology of periodontal diseases. American Academy of Periodontology. *J Periodontol.* 1996; 67 (9): 935-945.
8. Merigo E, Manfredi M, Meleti M et al. Jaw bone necrosis without previous dental extractions associated with the use of bisphosphonates (pamidronate and zoledronate): a four-case report. *J Oral Pathol Med.* 2005; 34 (10): 613-617.
9. Vescovi P. Osteonecrosi dei mascellari e bisfosfonati. *Terapia odontoiatrica e prevenzione. Tecniche Nuove, Milano,* 2008.
10. Grant BT, Amenedo C, Freeman K, Kraut RA. Outcomes of placing dental implants in patients taking oral bisphosphonates: a review of 115 cases. *J Oral Maxillofac Surg.* 2008; 66 (2): 223-230.
11. Lodi G, Sardella A, Salis A et al. Tooth extraction in patients taking intravenous bisphosphonates: a preventive protocol and case series. *J Oral Maxillofac Surg.* 2010; 68 (1): 107-110.
12. Statz TA, Guthmiller JM, Humbert LA, Johnson GK. Intravenous bisphosphonate-associated osteonecrosis of the jaw. *J Periodontol.* 2007; 78 (11): 2203-2208.
13. Freiburger JJ. Utility of hyperbaric oxygen in treatment of bisphosphonate-related osteonecrosis of the jaws. *J Oral Maxillofac Surg.* 2009; 67 (Suppl.5): 96-106.
14. Agrillo A, Ungari C, Filiaci F et al. Ozone therapy in the treatment of avascular bisphosphonate-related jaw osteonecrosis. *J Craniofac Surg.* 2007; 18 (5): 1071-1075.
15. Pires Oliveira DA, de Oliveira RF, Zangaro RA, Soares CP. Evaluation of low-level laser therapy of osteoblastic cells. *Photomed Laser Surg.* 2008; 26 (4): 401-404.
16. Romeo U, Galanakis A, Marias C et al. Observation of pain control in patients with bisphosphonate-induced osteonecrosis using low level laser therapy: preliminary results. *Photomed Laser Surg.* 2011; 29 (7): 447-452.
17. Hou JF, Zhang H, Yuan X et al. In vitro effects of low-level laser irradiation for bone marrow mesenchymal stem cells: proliferation, growth factors secretion and myogenic differentiation. *Lasers Surg Med.* 2008; 40 (10): 726-733.
18. Romeo U, Del Vecchio A, Palaia G et al. Bone damage induced by different cutting instruments an in vitro study. *Braz Dent J.* 2009; 20 (2): 162-168.

Corresponding Author: Gaspare Palaia

Department of Odontostomatologic and Maxillofacial Science, "Sapienza" University of Rome, Italy

e-mail: info@preventionandresearch.com



Autore di riferimento: Gaspare Palaia

Dipartimento di Scienze Odontostomatologiche e Maxillo Facciali, "Sapienza" Università di Roma

e-mail: info@preventionandresearch.com